VOL. 12, NO. 17, SEPTEMBER 2017 ISSN 1819-6608
ARPN Journal of Engineering and Applied Sciences

www.arpnjournals.com

MRI BRAIN TUMOUR SEGMENTATION AND IT'S 3D CONSTRUCTION

Ch. Rajasekhara Rao[1], M. N. V. S. S. Kumar[1] and G. Sasi Bhushana Rao[2]
[1]Department of Electronics and Communication Engineering, AITAM, Tekkali, India
[2]Department of Electronics and Communication Engineering, Andhra University, Visakhapatnam, India
E-Mail: muvvala_sai@yahoo.co.in

ABSTRACT

In the present world the death rate due to cancer, a malignant tumour is increasing day by day. Therefore, cancer detection is a challenging task to the doctors to detect it, in the preliminary stages. This detection can be done by identifying the tumour whether it is benign or malignant with help of Magnetic Resonance Imaging (MRI). In this paper, the MRI slices are segmented and then they are reconstructed to into 3D for better understanding the stage of tumour. First the MRI images are preprocessed and a new heuristic algorithm based on Expectation-Maximization, Histogram and object based thresholding methods is developed to identify the cancer wherein the resultant of the algorithm is 2D. For better understanding of the cancer stage these 2D images are combined to form a 3D view of the tumour. The performance of these hybrid fused techniques will be compared in terms of quality of the resultant tumor.

Keywords: tumor, MRI, segmentation, expectation-maximization, 3D modeling.

1. INTRODUCTION

The death rate due to tumor has been increasing enormously over the past three decades. Brain tumor is a pathology appearing in the intracranial anatomy due to abnormal and unstructured augmentation of cells. It is a very aggressive and life-threatening condition, which must be promptly diagnosed and cured to prevent mortality [1]. Brain tumors may be of different sizes and locations. They may be even overlapped with regular tissues. The uneven growth of tissue may be benign or malignant and may occur in several elements of the brain which may not be prime tumors. So it is very essential to identify tumors before reaching uncontrollable stage. The mechanism used to identify the tumors is MRI.

MRI is a sophisticated imaging method providing made data relating to the human soft-tissue structure which is largely engaged in radiology to observe the structure and behavior of the physical body. This will provide the intricated pictures of the body in all directions. MRI will be useful in brain, musculoskeletal, and cancer imaging as it offers a large amount of dissimilarity among the different soft tissues of the body [2]. This MRI image contains lots of information along with tumor.

In this paper an attempt is made to identify the tumor by developing a new hybrid algorithm based on Expectation-Maximization, Histogram and object based thresholding methods. The result obtained from this algorithm is in 2D format. For higher understanding of the tumor stage these 2D images are combined to create a 3D view of the tumor. The MRI slices considered for processing are show in Figure-1.

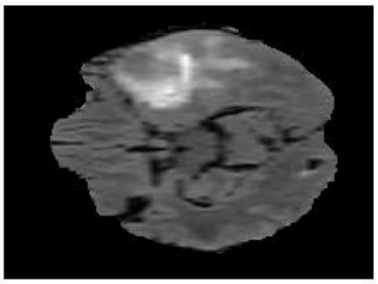

Figure-1. Slice of brain.

2. PROPOSED METHODOLOGY

To lessen the complexity and improve the correctness for tumor 3d reconstruction, the following steps are applied in the proposed algorithm, which is briefly described in this section. The block diagram of projected work is shown in Figure-2.

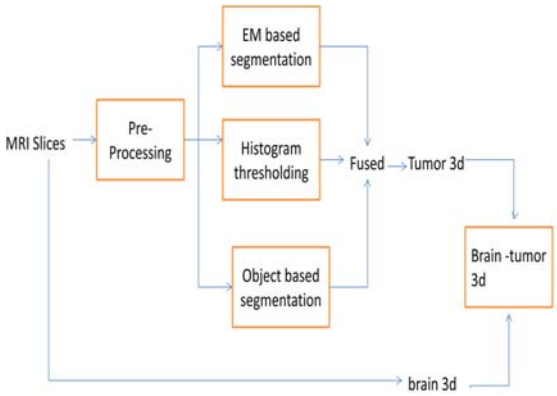

Figure-2. Flowchart of proposed algorithm.

3. PREPROCESSING

Before the presentation of the brain tumor segmentation methods, the MRI preprocessing operations are introduced because it is related to the traits of the

segmentation results. The raw MRI images need to be preprocessed to realize the segmentation purposes. These pre-processing operations include de-noising, skull-stripping, intensity normalization, etc, which will improve the results of brain tumor segmentation.

For clinical diagnosing, the visual quality of magnetic resonance images plays a crucial role. During acquisition or transmission MRI images are largely corrupted by noise. Noise is also created as a result of imperfect instrument used during processing, interference and compression. Noise in MRI poses a plenty of problem to medical personnel by interfering with interpretation of MRI for diagnosing and treatment of human [3]. Noise in MRI image makes it complex to accurately outline areas of significance amid brain tumor and regular brain tissues. So, it is required to denoise the MRI images to remove noise and to improve distinction between regions [4].

Image de-noising is a standard preprocessing task for MRI. Denoising is nothing but the removing of noise from image whereas retentive the initial quality of the image [1]. Since, the brain images are more sensitive than other medical images; MRI images are typically degraded by noises like Gaussian and Poisson. Generally, in almost all denoising algorithms the noise may be considered as additive white Gaussian noise [5].

By using wavelet transforms the noise can be reduced to large extent. The denoising of an image degraded by Gaussian noise is a regular problem image processing. To solve this problem wavelet transform is used in practice because of its energy compaction property. It decomposes the signal into wavelets and the coefficients are picked using thresholds and the signal is synthesized [6].

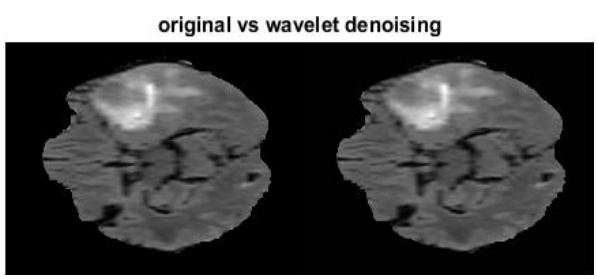

Figure-3. Wavelet denoising.

The discrete wavelet transform transforms the image content into an approximation subband and a set of detail subbands at different orientations and resolution scales. Typically, the bandpass content at every scale is split into 3 orientation sub-bands characterized by horizontal, vertical and diagonal directions. The approximation subband consists of the so-called scaling coefficients and the detail subbands are composed of the wavelet coefficients. Several properties of the wavelet transform, which make this representation attractive for denoising are easily recognized For denoising a medical image the Wavelets are being widely used [7]. The resultant of wavelet denosing is shown in Figure-3.

4. SEGMENTATION

Brain tumor segmentation aims to separate the different tumor tissues such as active cells, necrotic core, and edema from normal brain tissues of White Matter (WM), Gray Matter (GM), and Cerebrospinal Fluid (CSF). MRI brain tumor segmentation is drawing added attention in recent times because of its non-invasive imaging and good soft tissue distinction of MRI images [4].

Many methods are available which can produce good results for different imaging applications. But they are always not suitable for all types of applications and there is no unique segmentation algorithm which can produce good results.

Extraction of required information from all types of multidimensional images is playing a important role in image segmentation [8]. Manual separation of brain tissues for diagnosis purpose is more complex in terms of time and expertise. This leads to development of automated segmentation techniques.

4.1. EM based segmentation

Classification techniques are generally characterized as parametric and non parametric. In parametric approach, the maximum likelihood (ML) or maximum a posteriori (MAP) approach is used to estimate the model parameters and its optimization is done by using the Expectation–Maximization (EM) algorithm [9]. The cancer extracted using this method is shown in Figure-4.

The steps for implementation of EM algorithm are as follows:

a) Start: Assume that initial parameter set is (0).

b) E-step: At the tth iteration, parameter set is (t) and conditional expectation is calculated as,

$$Q(\theta \mid \theta^{(t)}) = E\left[\ln P(x, y \mid \theta) \mid y, \theta^{(t)}\right]$$

$$Q(\theta \mid \theta^{(t)}) = \sum_{x \in X} P(x / y, \theta^{(t)}) \ln P(x, y \mid \theta)_{x \in X}$$

where, X indicates set of labels.

c) M-step: Now, maximize $Q(\theta \mid \theta^{(t)})$ to obtain the next estimate:

$$\theta^{(t+1)} = \arg\max_{\theta} Q(\theta \mid \theta^{t})$$

then let $\theta^{(t+1)} \rightarrow \theta^{(t)}$ and repeat from the E-step.

In the EM algorithm, we do MAP estimation and solve for x* that minimizes the total posterior energy

$$X^{*} = \arg\min_{X} \{U(Y \mid X, \theta) + U(X)\}$$

$$X* = \arg\max_{x} \{P(Y \mid X, \theta) P\{X\}\}$$

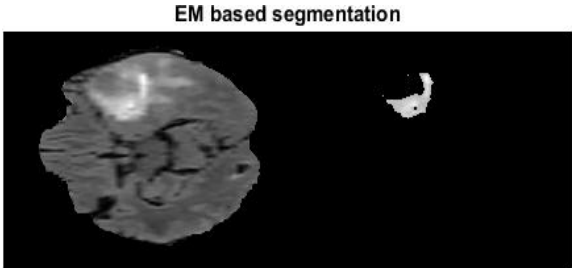

Figure-4. EM segmented slice.

4.2. Histogram based thresholding

Histograms of brain Magnetic Resonance Imaging images indicate a classic form, wherein the thresholding is done by parameters which may not vary considerably from one patient to another. In fact, it appears that brain MRI histograms are often bimodal which represents the foremost common intensity values such as the image background and all grey values. In our case, for every patient 2 magnetic resonance imaging modalities (T1C and FLAIR) are used to extract the 2 corresponding histograms. Generally, edema region is brighter (higher intensity) on FLAIR than on T1C and therfore the gadolinium-enhanced lesion has the alternative behavior [10]. The cancer extracted using this method is shown in Figure-5.

Step1: The MRI image is separated into two identical parts about its central axis and the histogram for each part is obtained.

Step2: Threshold is calculated by comparing to histograms.

Step3: By using threshold, segmentation is done for two equal parts.

Step4: Identified matter is cropped along its outline to get the dimension of the tumor.

Step5: Construct an image of the original size. By checking the segmented image pixel value and 255 will be assigned if it is greater than threshold value or else 0 will be assigned.

Step6: Segment the tumor area.

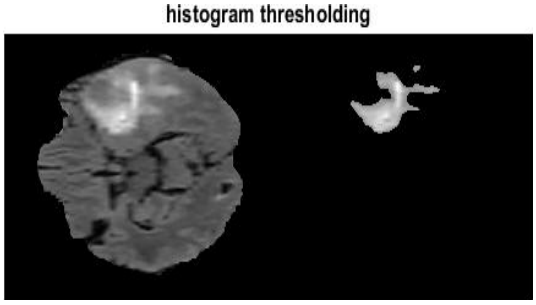

Figure-5. Result of histogram thresholding.

4.3 Object based thresholding

The Object Based Thresholding technique is more suitable for images with completely different intensities. In this the image is divided into various regions based on the intensity values [8]. For implementing thresholding technique, let us consider f(x,y) be the input image and 'T' be the threshold value then the segmented image g(x,y) is given by,

$$g(x,y) = \begin{cases} 0, & f(x,y) \le T \\ 1, & f(x,y) > T \end{cases} \quad (1)$$

The image can be segmented into two groups using equation (1). The threshold value is applied to a selected region and segments the image objects that are different in intensity from their surroundings. Whereas the global thresholding is suitable only to images which contains objects with uniform intensity or the contrast between the objects and the background is high. The cancer extracted using this method is shown in Figure-6.

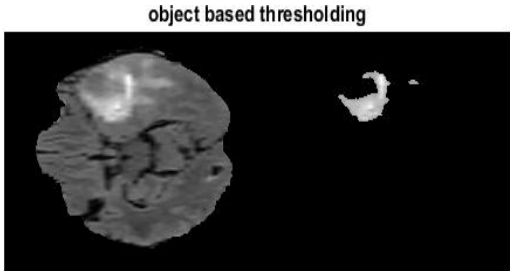

Figure-6. Result of object based thresholding.

4.4 Proposed fusion algorithm

The MRI brain image is subjected to above mentioned segmentation algorithms such as EM based segmentation, histogram based thresholding and object based thresholding individually and then the results are combined (fused) pixel by pixel based on the maximum criterion to attain the absolute segmented image. The proposed fused technique exhibits better segmentation results comparing with individual segmentation algorithms. The cancer extracted using this method is shown in Figure-7.

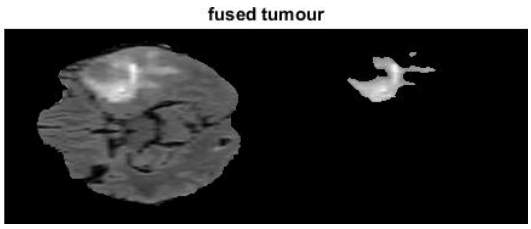

Fgure-7. Result of proposed fusion algorithm.

5. 3D CONSTRUCTION OF MRI SLICES

Since Doctors had only the 2D Image Data to visualize the tumors in the MRI images, with which it is very difficult to imagine how the tumor would exactly look like, a 3D model of the tumour is developed. The doctors were underprivileged from the exact visualization of the tumor, the amount of the tumor to be removed by operation was not known, which caused a lot of deformation in the faces and structure of the patients face

or skull. Hence to visualize the tumor properly 2D MRI image has to be converted to 3D image [11] [15]. As the 3d modelling softwares, computer image processing technology are improving day by day, 3D visualization has become a significant means of the medical diagnose. They are offering rich and precise information for medical experts. Thus in follow, radiation oncologists pay a considerable portion of their time performing the extraction of 3D objects and its visualization [12]. So a 3D brain tumor segmentation algorithm is developed by stacking a sequence of 2D tumor contours, detected by 2D level-Sets method in the parallel cross-sectional magnetic resonance imaging images [13]. The important steps to make 3D models and volume rendering from 2D slice images: [14]

a) Create an empty 3D volume.

b) All the x and y coordinates of image pixels in 2D image are projected to the empty 3D volume. The resolution with which the MRI images are obtained is considered as distance between images and is taken as z coordinate. Now all the edge pixels are connected together.

c) The above steps are repeated for all the MRI images and all the points in the 3D volume will be connected together.

d) To render the stacked images, the 3D volume is held in a rectangular cube as all 2D MRI images are of having equal dimensions. The position of the tumor inside the brain can be visualized clearly, as the brain outline in the 3D model is presented with a high degree of transparency.

6. RESULTS

Firstly the 2D MRI slices are extracted from mha file. These images are preprocessed for denoising. Now by applying existing segmentation methods and developed method caner is identified as shown in above results. All the information extracted is in 2D. So for better understanding of the caner features like size, position etc. it is very essential to construct 3D view. The results for 3D view are shown in Figure-8. Later this 3D view of cancer is fused with original magnetic resonance imaging slices for better view as shown in Figure-9. The volume of the tumor in terms of pixels for existing segmentation methods and developed method is shown in Table-1. From the Table-1 it is found that, the developed method performed well by preserving the edges also.

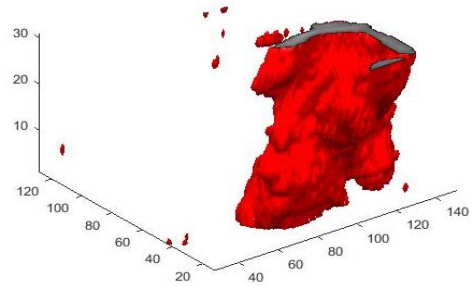

Figure-8. 3D tumor.

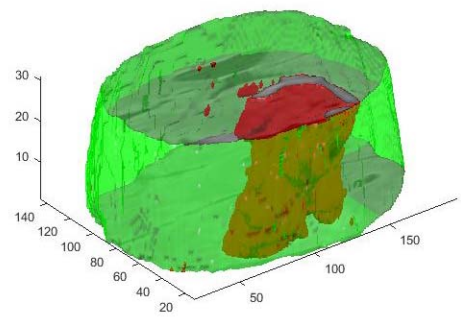

Figure-9. Actual view of 3D tumor in brain.

Table-1. Volume of the cancel in terms of Pixels.

Method	EM based segmentation	Histogram based segmentation	Object based thresholding	Proposed algorithm
Number of pixels in tumor	19759	40097	26301	42347

CONCLUSIONS

In this paper a new hybrid algorithm based on based on Expectation-Maximization, Histogram and object based thresholding methods is developed to identify the tumour in the MRI slices. Initially 2D MRI slices are extracted from the dataset and these slices are denoised using wavelets. Later developed algorithm is applied on to the MRI slices to identify the tumour. In order to have the complete information of the cancer, the signature in all three dimensions is needed. Therefore these images are processed to extract the 3D signature of the tumour; thereby whether the tumour is benign or malignant can be identified. Among all the algorithms, the proposed algorithm segmented the image well by retaining the edge pixels which provides good volume of the tumor in terms of pixels.

REFERENCES

[1] Muhammad Nasir, Asim Baig and Aasia Khanum. 2014. Brain Tumor Classification in MRI Scans Using Sparse Representation. Springer International Publishing Switzerland 2014, A. Elmoataz *et al*. (Eds.): ICISP 2014, LNCS 8509, pp. 629-637.

[2] D. Selvaraj, R. Dhanasekaran. 2013. Mri Brain Image Segmentation Techniques - A Review. Indian Journal of Computer Science and Engineering (IJCSE), ISSN: 0976-5166, 4(5).

[3] Sayali SavajiPP, Parul Arora P. 2012. Denoising of MRI Images using Thresholding Techniques through Wavelet. International Journal of Science, Engineering and Technology Research (IJSETR). 1(3).

[4] Jin Liu, *et al*. 2014. A Survey of MRI-Based Brain Tumor Segmentation Methods. Tsinghua Science and Technology. ISSN ll1007-0214ll04/10llpp578-595, 19(6).

[5] Eman Abdel-Maksoud, Mohammed Elmogy, Rashid Al-Awadi. 2015. Brain tumor segmentation based on a hybrid clustering technique. Egyptian Informatics Journal.

[6] Shashikant Agrawal, Rajkumar Sahu. 2012. Wavelet Based MRI Image Denoising Using Thresholding Techniques. International Journal of Science, Engineering and Technology Research (IJSETR). 1(3).

[7] Aleksandra Pi_zurica, Alle Meije Wink, Ewout Vansteenkiste, Wilfried Philips and Jos B.T.M. Roerdink. 2005. A review of wavelet denoising in MRI and ultrasound brain imaging. Current Medical Imaging Reviews.

[8] Nelly Gordillo, Eduard Montseny, Pilar Sobrevilla. 2013. State of the art survey on MRI brain tumor segmentation. Magnetic Resonance Imaging.

[9] Saurabh Shah and N C Chauhan. 2015. "An Automated Approach for Segmentation of Brain MR Images using Gaussian Mixture Model based Hidden Markov Random Field with Expectation Maximization. 2(4).

[10] Mohamed Ben Salah, Idanis Diaz, Russell Greiner, Pierre Boulanger,Bret Hoehn, and Albert Murtha. 2013. Fully Automated Brain Tumor Segmentation Using Two MRI Modalities. Springer-Verlag Berlin Heidelberg 2013 ISVC 2013, Part I, LNCS 8033, pp. 30-39.

[11] Megha Borse, S.B. Patil, B.S.Patil. 2013. Literature Survey for 3d Reconstruction of Brain Mri Images. International Journal of Research in Engineering and Technology eISSN: 2319-1163 | pISSN: 2321-7308, 02(11).

[12] Megha P. Arakeri and G. Ram Mohana Reddy. 2013. An Effective and Efficient Approach to 3D Reconstruction and Quantification of Brain Tumor on Magnetic Resonance Images. International Journal of Signal Processing, Image Processing and Pattern Recognition. 6(3).

[13] Kamel Aloui and Mohamed Saber Naceur. 3D Tumor Segmentation from Volumetric Brain MR Images Using Level-Sets Method. 20267.

[14] Naveenkumar.R, Sanjay D.S. 2014. Morphological Image Processing Approach For 2d To 3d Reconstruction of Brain Tumor from Mri Images And Volume Calculation of Tumor. Proceedings of 3rd IRF International Conference, 10th May, Goa, India, ISBN: 978-93-84209-15-5.

[15] Sheng-Chih Yang, *et al*. 2015. Reconstruction of three-dimensional breast-tumor model using multispectral gradient vector flow snake method. Journal of Applied Research and Technology. 13: 279-290.