VOL. 13, NO. 10, MAY 2018 ISSN 1819-6608
ARPN Journal of Engineering and Applied Sciences

www.arpnjournals.com

A REVIEW OF ECHOCARDIOGRAPHIC IMAGE SEGMENTATION TECHNIQUES FOR LEFT VENTRICULAR STUDY

Ms. Pallavi Kulkarni[1] and Deepa Madathil[2]
[1]Electronics and Communication Department, M. V. J College of Engineering Bangalore, Karnataka, India
[2]School of Electronics Engineering Vellore Institute of Technology, Vellore, Tamil Nadu, India
Email: deepa.madathil@gmail.com

ABSTRACT

Ecocardiographic image segmentation has gained importance with the development of various image processing techniques. This is vital step as it gives methodology to evaluate many cardiac parameters such as LV volume, thickness of heart wall, ejection fraction, motion of valves etc. These parameters are essential to diagnose the health of a heart. Manual segmentation techniques are time consuming and require trained operators to perform the task. This process can be simplified with precision by various semi-automatic and automatic image segmentation techniques. This paper reviews different echocardiography image segmentation methods for left ventricle border detection. The methodology proposed by authors is presented with validation criteria used for their performance. Segmentation methods are classified in the broad groups as per the approach used. Finally the summary of the various methods is presented along with their methodology and performance measures.

Keywords: echocardiography, image segmentation, left ventricle, active contour, level set.

1. INTRODUCTION

Echocardiography is a technique used to get real time images of heart structure using ultrasound waves. Main advantages of echocardiography are low cost of operation, non-invasive, widely available and it causes minimal discomfort to patient. To assess the heart functionality, it is required to obtain different cardiac parameters such as the thickness of heart wall, the enclosed area, the variation of these shape attributes throughout the cardiac cycle etc. These shape attributes are acquired by identifying endocardial (inner) and epicardial (outer) boundaries of the heart wall. This outlining of the boundaries is achieved by echocardiographic image segmentation techniques. Image segmentation is the process of partitioning of an image into a set of separate regions, the combination of which form the original image. The image is divided into different segments which have similar properties like gray intensity levels, texture, colour etc. Various automated and semi-automated methods are developed over the period to perform this task. These methods can provide reliable and consistent results than manual segmentation which is time consuming and defers for each individual.

2. IMAGE SEGMENTATION METHODS IN ECHOCARDIOGRAPHY

Major research in echocardiography image segmentation is done on the left ventricle and in particular to the endocardium and myocardium since it performs a task of pumping the oxygenated blood. It also allows estimating LV volumes/areas, ejection fraction, regional wall motion tracking etc. Automated segmentation of echocardiography images possesses many challenges in its implementation. Many times echocardiographic image segmentation suffers from inferior quality of images. There are different artifacts arising due to ultrasound equipments such as speckle noise, attenuation, shadow from lungs, signal dropout etc. Also image parameters like lower intensity gradients, discontinuous borders, variation in collected data due to orientation and positioning of transducer can make the segmentation task complicated. There is no definite relation between pixel intensity and its physical property or its position. Many times regions/tissues are not distinguishable by their intensity value or texture.

Different segmentation methods are developed from the image processing techniques such as edge based methods, active contour methods, level set methods, thresholding methods, intensity gradient based methods, region growing methods, artificial neural network, fuzzy clustering etc. In recent years, research is also being done in 3D echocardiography segmentation. Several methods to perform the 3D segmentation of the LV have become available in literature e.g. [1]. Representative images of segmentation techniques are given below; Figure-1 shows the boundary detection and tracking of left ventricle. Figure-2 shows 3D echocardiography image segmentation in cardiac cycle.

3. REVIEW OF RESEARCH ON SEGMENTATION METHODS

In this section, we have reviewed various researches and prior studies carried out in the field of echocardiography image segmentation methods.

A. Active contours

In image segmentation, deformable models are very widely used methods. Deformable models became popular after the publication by Kass *et al* [2] in their research paper 'Snakes: Active contour models' which was published in 1987. These are also called by many researchers as active contours.

The base of deformable models is the energy minimization. It is basically searching of parametric curve that minimizes weighted sum of internal energy and

potential energy. Internal energy specifies tension or smoothness of

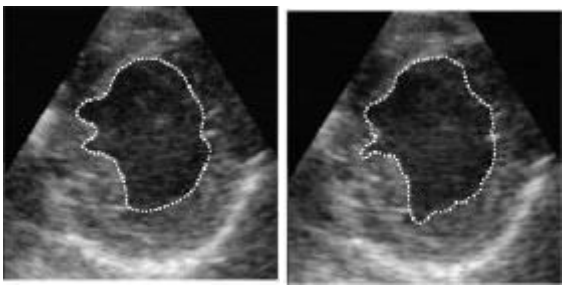

Figure-1. Tracking of endocardial border of the left ventricle (short axis view) [8].

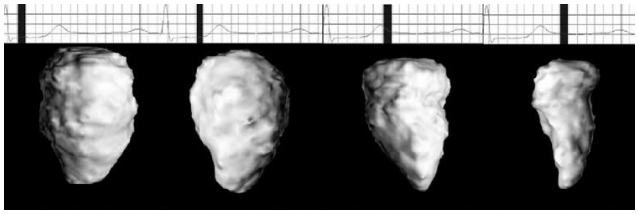

Figure-2. LV surface detection on 3D data during the phases of cardiac cycle (short axis view) [1].

contour. The potential energy is defined in the image domain. It usually has minimal value at the point of high intensity gradient which is usually at the object edge. Total energy minimization occurs when internal and external energies are equal [4].

Active contour or snake is a flexible curve that detects specified features within an image dynamically. The energy function can be written as [2],

$$E_{snake} = \int_0^1 (E_{int}(v(s)) + E_{image}(v(s)) + E_{con}(v(s))ds)$$

Where,

E_{int} = the internal energy - summation of an elastic energy and a bending energy. It applies piecewise smoothness constraint to contour.

E_{image} = Energy of image. It represents forces pushing the snake toward image features (edges)

E_{con} = external energy useful in placing the snake near the desired local minimum

The concept of active contour or snake is used in segmentation of echocardiography by many authors.

Bharali *et al* [5] have proposed unsupervised, fully automatic method for LV segmentation. Active contour method is used for segmenting and simultaneous tracking of LV in echocardiography image sequences. In preprocessing stage, histogram modification approach for image enhancement is used along with Discrete Wavelet Transform (DWT) filter for image denoising. This processed image is used to give initial approximation of the contour using K-means clustering in the first image of sequence, as proposed by [6]. The final contour obtained in the previous frame using active contour method is used as the initial contour for every frame in the sequence. The proposed method is used for clinical data, and found to track the heart wall with high precision and accuracy.

Skalski *et al*. [7] presented an application of active contour without edge method to left ventricle segmentation in ultrasound echocardiographic images. The proposed procedure consists of three basic modules: ROI calculation by means of Hough transform, image de-noising by means of speckle noise anisotropic diffusion (SRAD) filtration and, finally, image segmentation by means of active contour without edges method. The proposed scheme can be modified with deformable image registration methods, like B-Spline Free Form Deformation or Spring Mass system can be used for calculation of deformations of the heart's structures like heart walls.

The semi-automatic segmentation method proposed by Mikic *et al* [8], implements active contour method. For tracking the echocardiography image sequences, optical flow information is used. A technique is developed to incorporate the pixel velocities data to estimate the initial contour in subsequent frames enabling the tracking of fast-moving objects. This algorithm was tested on several ultrasound echocardiography images. The contour successfully tracked boundaries of mitral valve leaflets, aortic root and endocardial borders of the left ventricle.

Mishra *et al* [9] developed a method to use genetic algorithm (GA) for contour optimization in an active contour model. The snake energy of active contour is the objective function which is minimized using GA. An image preprocessing is suggested to automatically initialize the contour. Gaussian low pass filter and morphological operations were used to filtering and thresholding the initial contour. In optimizing the energy of the snake, nonlinear mapping of intensity gradient is considered. The tracking of a motion of the boundary is achieved by considering the optimized contour as initial contour for next frame. The result obtained by the proposed GA based approach is compared with conventional nonlinear programming methods. Also it is compared to manual delineation done by two experts on 20 frames. The correlation of 0.92 is achieved between area enclosed by contours from proposed method and manual tracing.

Multiple active contours model is used by Chalana *et al* [10] for identifying the endocardial and epicardial borders in short axis echocardiography images. They used a concept that a surface can be represented by two planer curves. It can be considered as special case of active contour method. These planer curves in turn form the endocardial and epicardial borders. For active contour algorithm they used image intensity gradient as attracting force. Tracking is also smoothened by using temporal continuity across frames which constraints motion between two consecutive images. The proposed method is tested on 44 clinical datasets which were also delineated manually by experts. The area correlation coefficient was 0.95 for epicardium and 0.91 for endocardium.

Jacob *et al* [11] developed method for epicardium and endocardium border tracking based on dynamic contour tracking approach. It is a Kalman-filter based technique which combines image measurements such as intensity gradient based feature detector and contour model. The contour model is spatio-temporal model. It has two components; a shape-space-model describing the deformation of the contour, and a motion-model describing the temporal properties of the contour for tracking. Shape-space model allows incorporation of prior anatomical knowledge into the tracker. The algorithm was also extended for myocardial tracking. The algorithm was tested on stress echocardiography dataset. Correlation coefficient with manual delineation is found to be 0.98 for area of LV obtained.

Active contour method is efficient and accurate way to find edges. These methods can also be used for tracking the boundary in motion. Limitation of active contour methods is that user needs to initialize the rough contour of boundary. This may lead to variation in results depending on the experience of user.

B. Level set

In level set method a dynamic surface is represented implicitly, motion of which is governed by partial deferential equation. Among the deformable models, the active contour model and the level set model are the most popular and effective approaches in segmentation. The active contour model can be viewed as a parametric model, whereas level set model is a geometric deformable model.

Malladi and senthian *et al* [12] developed level set approach which is a generic numerical method for evolving fronts in implicit form. Topological changes in the boundary are better handled by level set method than active contour method. There are numerous researches for use of level set method in segmentation of echocardiography images. Later Senthian [13] had proposed fast marching method to solve PDE more efficiently using narrow band approach.

Yan *et al* [14] used Fast marching method to detect and track the endocardial boundary in echocardiography images. Instead of using local image intensity gradient for calculation of speed term in Level set equation, they have used average energy based on average intensity gradient in speed term. Corsi *et al* [1] presented a study in which the level set formulation of interface motion has been applied to extract LV endocardial surfaces from a sequence of cardiac ultrasound data. Real time 3D Echocardiography was processed by authors, which was obtained by a real time volumetric ultrasound imaging system. Initial condition for level set PDEs is obtained by selecting some feature points close to LV boundaries. These feature points are chosen on the number of slices made in the volume. Linear interpolation is performed on the slices (feature points) to fill up the initial volume. The segmentation method is tested on in vitro (balloons) and in vivo (25 patients LV data). High correlation coefficients (r=0.99 for in vitro and r = 0.97 for in vivo) were obtained LV volume and EF calculations.

Lin *et al* [15] used combination of edge and region information in level set formulation. The method is automatic as initialization of the contour is done by using additive Gaussian noise model. Then refinement of initial course boundary is done by region and edge based level set algorithm. Dataset used for checking the method was rotational 3D echocardiography images. These are sliced across to obtain 2D planes for segmentation. Comparison is done on 24 echocardiography images with manual delineation by experts with mean absolute distance of 1.643 pixels.

Level set methods are robust in nature and are able to handle sharp corners and cusps in contours. They can also capture topological changes and 3D effects. The drawback of this method is they are numerically costly. Also requires appropriate advancing velocities to accurately capture edges.

C. Intensity gradient methods and variants

Intensity gradient methods utilize abrupt changes in the gray level of pixels at the edges of an object in image. An approach given by Chu *et al* [18] uses image intensity variation for initial contour extraction. Image smoothing and noise reduction are done by using large window Gaussian filter. Final refinement is done by using high level information about heart wall and labeling the detected boundary in initial stages by comparing. The algorithm is tested for endocardium and epicardium extraction of 16 images. Correlation coefficient was 0.995 for inner boundary and 0.997 for outer boundary. Bansod *et al* [19] used an interesting approach of radial gradient search and temporal smoothing for LV detection and tracking. For finding the region of interest which encloses LV, Hough transform and image statistics are used. LV center point was obtained using image intensity information in ROI. Then the boundary pixels were identified by radial gradient search. Boundary smoothing is achieved by least squares linear polynomial fitting. Further refinement is done by temporal smoothing by getting the border pixels information from the neighboring frames. The method is compared on 10 echocardiography videos against manual tracking by experts with mean error of 2 mm at different levels of LV. Major limitation of this method is unavailability of clear distinction between in gray scale intensities in echocardiographic images.

D. Neural network and fuzzy logic

Different techniques such as neural network and fuzzy logic are also implemented for echocardiography image segmentation. Setarehdan *et al* [16] described automatic fuzzy multire solution based algorithm for left ventricle boundary detection and its tracking. Initially center point in the LV is approximately defined using fuzzy techniques based on image intensity. Then the epicardial and endocardial boundary edge points are searched on radial lines originating from the center point using a fuzzy multiscale edge detection technique (FMED). These edge points are smoothened spatially and temporally using cubic B-Spline technique. Wavelet based filter is used for noise reduction. Results are compared for

14 datasets of echocardiography images (short axis views). Correlation between described technique and manual outlining of boundaries is 0.96 for endocardial borders and 0.94 for epicardial borders. Rekeczky *et al* [17] used Cellular neural network (CNN) based spatio-temporal approach to find and track the LV endocardial boundary. Nonlinear filtering is used to remove the speckle noise from the image.

Table-1. Summary of echocardiographic image segmentation techniques.

Author [Ref]	Year	Method	Dimension	User interaction	Performance measure	Comparison
Chu [18]	1988	Intensity Gradient Prior Knowledge	2D	Automatic	R = 0.997 for epicardium R = 0.995 for endocardium	Manual Delineation
Chalana [10]	1996	Multiple Active contour method	2D	Manual contour initialization	R = 0.95 for epicardium R = 0.91 for endocardium	Manual Delineation
Mikic [8]	1998	Active contour method	2D	Manual contour initialization	LV, MAD = 1.148 mm, R = 0.99 Mitral valve, MAD = 2.14 mm Aortic Root MAD = 1.53 mm	Manual Delineation
Setarehdan [16]	1999	Fuzzy Method	2D	Fuzzy Database creation	R = 0.94 for epicardium R = 0.96 for endocardium	Manual Delineation
Jacob [11]	2002	Shape space based dynamic contour	2D	Manual contour initialization	R = 0.92	Manual Delineation
Corsi [1]	2002	Level set	3D	Manual feature point definition	R = 0.97	Manual Delineation
Bosch [20]	2002	Active Appearance Model	2D	Database/training image set creation	97% match	Manual Delineation
Mishra [9]	2003	Active contour method with GA optimization	2D	Automatic	R = 0.92	Manual Delineation
Lin [15]	2003	Level set with knowledge prior	3D	Automatic	MAD = 1.643 pixels	Manual Delineation
Bharali [5]	2006	Automatic active contour method	2D	Automatic	Visual Observation	--
Bansod [19]	2007	Radial Gradient search , Hough Transform	2D	Automatic	Mean error = +-2 mm	Manual Delineation
Hansegard [21]	2007	Active Appearance Model	Tri-plane Echo	Database/training image set creation	LV volume diff. End diastole = 3.1 ml End systole = 0.61 ml EF = 6.1%	Manual Delineation
Skalski [7]	2012	active contour without edge , Hough Transform	2D	manual center initialization	Visual Observation	--
Huang [22]	2012	Sparse representation; Level Set	2D	Creation of appearance dictionaries	MAD = 0.56 mm	Manual Delineation
Bernard [23]	2016	Evaluation system for segmentation methods	3D	User interaction for comparison Criteria	--	Manual Delineation

E. Prior knowledge database guided methods

Active shape model (ASM) and active appearance models (AAM) are developed by Cootes and Taylor utilize expert prior knowledge in global shape and texture of model in image segmentation. Bosch *et al* [20] used active appearance motion model AAMM which is an extension of AAM in finding shape and appearance endocardium, also tracking its motion. Hansegard *et al*

[21] used constrained AAM for left ventricle segmentation in tri-plane echocardiograms. The model is constrained to manually defined contour points in the domain. This shows improvement in the volume and ejection fraction estimates. Another prior knowledge based approach is used by Huang *et al* [22]. They have used sparse appearance representation for segmenting left ventricular endocardial and epicardial boundaries. Spatio-temporal coherence constraints are used for tracking frames. Separate appearance dictionaries are created for blood and tissues. These are updated in a boosting framework as the consecutive frames of echo images are segmented. These dictionaries discriminate images by representing in sparse coding over patch of image. After that region based level set algorithm is used. Results are compared for 2d echocardiography against manual delineation with mean absolute distance of 0.56 mm.

Bernard *et al* [23] tried to formulize and setup standardized evaluation criteria for different segmentation methods. They have used 3D echocardiographs of 45 different patients from three different hospitals. Total 9 segmentation methods (5 fully automatic and 4 semi-automatic methods) are considered to compare their performance. Three expert cardiologists have manually delineated the 3DE to form the basis for comparison. The evaluation parameters used are segmentation accuracy (mean surface distance, Hausdorff surface distance etc.), clinical performance parameters (mean, SD of LV volumes, ejection fraction). Their evaluation showed machine learning techniques methods performed better followed by deformable models.

Summary of various segmentation techniques reviewed in this paper is presented in table I along with its performance evaluation measure. Abbreviations used in table are: (1) R = Correlation coefficient, (2) MAD = Mean absolute distance between reference image and segmented image, (3) EF = Ejection fraction

4. CONCLUSIONS

We have discussed application of image segmentation techniques in the area of echocardiography. Various influential researches in segmentation are presented. Active contour method and its variations are most popular among the researchers. Level set methods can accurately handle topology changes and are stable in nature. Intensity gradient approach is numerically cheap but has limited application in echocardiography owing to presence of noise, missing boundaries, no clear distinction in image regions. Newer methods like active appearance model, active shape models, fuzzy methods and machine learning methods are finding increasing research interest in the field of echocardiographic image segmentation. Summary of the papers reviewed with their performance evaluation is presented at the end.

Some of the segmentation methods require initialization of the contour for the onset of boundary detection. This could lead to variability in the results depending on the initial condition specified by users. Many researchers [4, 8, 14, 19 etc] have suggested methods to automatically initialize the contour to eliminate the user dependency.

Was lack of standardized performance comparison procedure or database for segmentation methods? Bernard *et al* [23] have suggested methods to overcome this issue by providing various statistical and clinical performance parameters. Majorly segmentation methods rely on manual delineation by experts for comparison, which may lead to inter-observer variation.

Robustness and reliability of segmentation method in echocardiography can be improved by utilizing combinations of physical information in image, prior anatomical knowledge, temporal constraints in tacking frames, intensity and shape constraints.

REFERENCES

[1] C. Corsi, G. Saracino, A. Sarti, C. Lamberti. 2002. Left ventricular volume estimation for real-time three-dimensional echocardiography. IEEE Transactions on Medical Imaging. 21(9).

[2] M. Kass, A. Witkin, D. Terzopoulos. 1988. Snakes: Active contour models. International Journal of Computer Vision. 321-331.

[3] J. Alison Noble, Djamal Boukerroui. 2006. Ultrasound Image Segmentation: A Survey. IEEE Tranactions on medical imaging. 25(8).

[4] Marián Bakoš. 2007. Active Contours and their Utilization at Image Segmentation. 5th Slovakian-Hungarian Joint Symposium on Applied Machine Intelligence and Informatics, January 25-26.

[5] U Bharali D ghosh. 2006. Cardiac Motion Estimation from Echocardiographic Image Sequence using Unsupervised Active Contour Tracker. 9th International Conference on Control Automation Robotics & Vision.

[6] K. Humnabadkar, S. Singh, D. Ghosh and P. K. Bora. 2003. Unsupervised active contour model for biological image segmentation and analysis. Proc. IEEE Region 10 – Asia-Pacific Conf. (TENCON). 2: 538-542.

[7] A. Skalski, P. Turcza, T. Zieli_ski, J. Królczyk, T. Grodzicki. 2010. Left Ventricle USG Image Segmentation Using Active Contour Model. International Conference on Computational Science, ICCS.

[8] Ivana Mikic, Slawomir Krucinski, and James D. Thomas. 1998. Segmentation and Tracking in Echocardiographic Sequences: Active Contours

Guided by Optical Flow Estimates. IEEE Transactions on Medical Imaging. 17(2).

[9] A. Mishra, P. K. Dutta and M. K. Ghosh. 2003. A GA based approach for boundary detection of left ventricle with echocardiographic image sequences. Image Vis. Compute. 21: 967-976.

[10] Chalana V., Linker D. T., Haynor D. R. & Kim Y. 1996. A multiple active contour model for cardiac boundary detection on echocardiographic sequences. IEEE Transactions on Medical Imaging. 15, 290-298.

[11] Gary Jacob, J. Alison Noble, Christian Behrenbruch, Andrew D. Kelion and A. P. Banning. 2002. A Shape-Space-Based Approach to Tracking Myocardial Borders and Quantifying Regional Left-Ventricular Function Applied in Echocardiography. IEEE Transactions on Medical Imaging. 21(3).

[12] Ravikanth Malladi, James A. Sethian and Baba C. Vemuri. 1995. Shape Modeling with Front Propagation: A Level Set Approach. IEEE Transactions on Pattern Analysis and Machine Intelligence. 17, 2, pp. 158-175.

[13] J. A. Sethian. 1999. Level set methods and fast marching methods: evolving interfaces in computational geometry, fluid mechanics, computer vision, and materials science. Cambridge Universtiy Press.

[14] J. Y. Yan and T. Zhuang. 2003. Applying improved fast marching method to endocardial boundary detection in echocardiographic images. Pattern Recognit. Lett. 24(15): 2777-2784.

[15] N. Lin, W. C. Yu and J. S. Duncan. 2003. Combinative multi-scale level set framework for echocardiographic image segmentation. Med. Image Anal. 7(4): 529-537.

[16] S. K. Setarehdan and J. J. Soraghan. 1999. Automatic cardiac LV boundary detection and tracking using hybrid fuzzy temporal and fuzzy multiscale edge detection. IEEE Trans. Biomed. Eng. 46(11): 1364-1378.

[17] C. Rekeczky, A. Tahy, Z. Vegh and T. Roska. 1999. CNN-based spatiotemporal nonlinear filtering and endocardial boundary detection in echocardiography. Int. J. Circuit Theory Appl. 27(1): 171-207.

[18] Chu C. H., Delp E. J. & Buda A. J. Detecting left ventricular endocardial and epicardial boundaries by digital two dimensional echocardiography. IEEE Transactions on Medical Imaging. 7, 81-90.

[19] Prashant Bansod, U.B. Desai, Nitin Burkule. 2007. Automatic detection of left ventricle in echocardiographic sequences using radial search and temporal smoothing. 15th International Conference on Digital Signal Processing.

[20] J. G. Bosch, S. C. Mitchell, B. P. F. Lelieveldt, F. Nijland, O. Kamp, M. Sonka and J. H. C. Reiber. 2002. Automatic segmentation of echocardiographic sequences by active appearance motion models. IEEE Trans. Med. Imag. 21(11): 1374-1383.

[21] Jøger Hansegård, Stig Urheim, Ketil Lunde and Stein Inge Rabben. 2007. Constrained Active Appearance Models for Segmentation of Triplane Echocardiograms. IEEE Transactions on Medical Imaging. 26(10).

[22] Xiaojie Huang, Ben A. Lin, Colin B. Compas, Albert J. Sinusas, Lawrence H. Staib and James S. Duncan. 2012. Segmentation of Left Ventricles from Echocardiographic Sequences via Sparse Appearance Representation. IEEE Mathematical Methods in Biomedical Image Analysis.

[23] Bernard O., Bosch J. G. *et al*. 2016. Standardized Evaluation System for Left Ventricular Segmentation Algorithms in 3D Echocardiography. IEEE Trans Med Imag. 35(4): 967-977.